Volume Visualization

Rakesh Mullick
NIH-CC-DRD
rmullick@nih.gov

Overview

Research & Development Interests

- **Interactive Volume Rendering**
- **Volume Data Analysis & Quantification**
- **Collaborative Visualization**
- **PlugIn Architecture**

Posterior Tibialis Tendon (MR)

- 2D Post Contrast Axial FMPSPGR data (TR/TE/Flip Angle: 150/6/60) 256x256x34 0.55mmx0.55mmx3.0mm

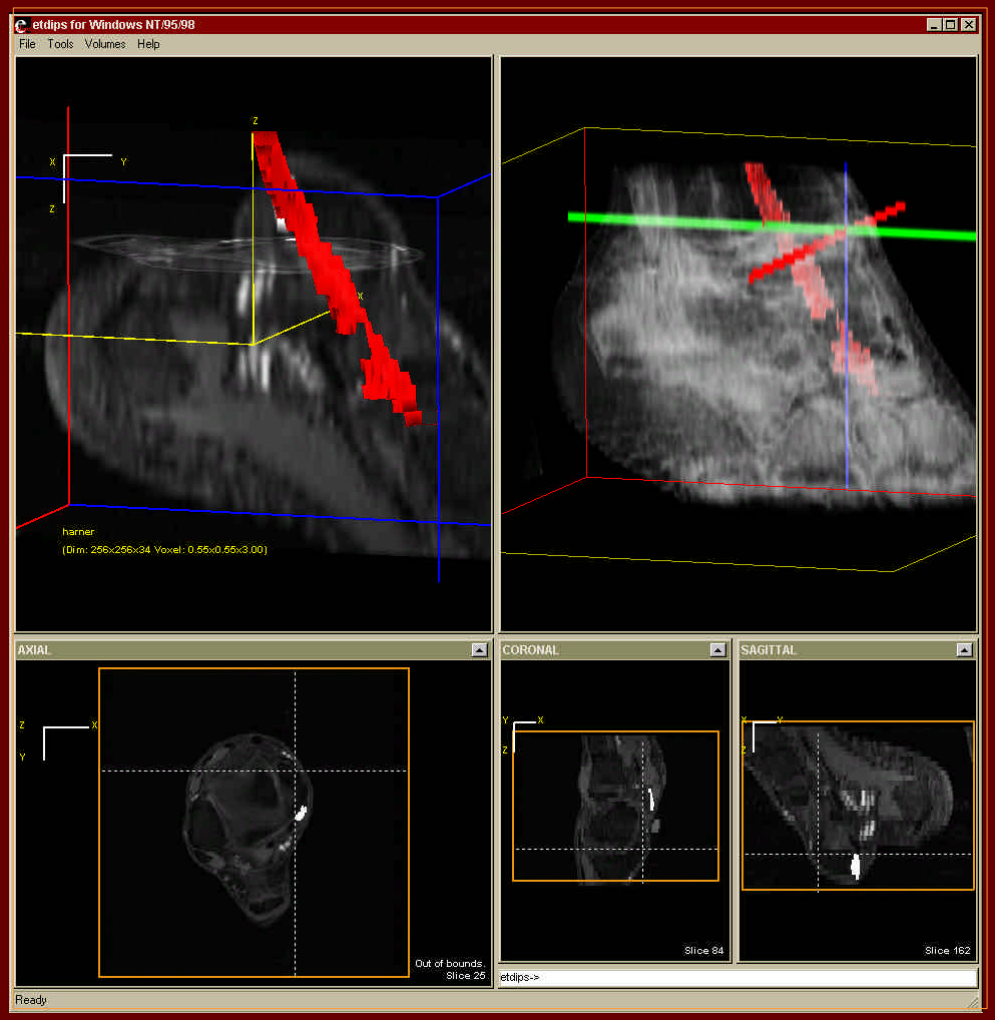

Peritendinitis

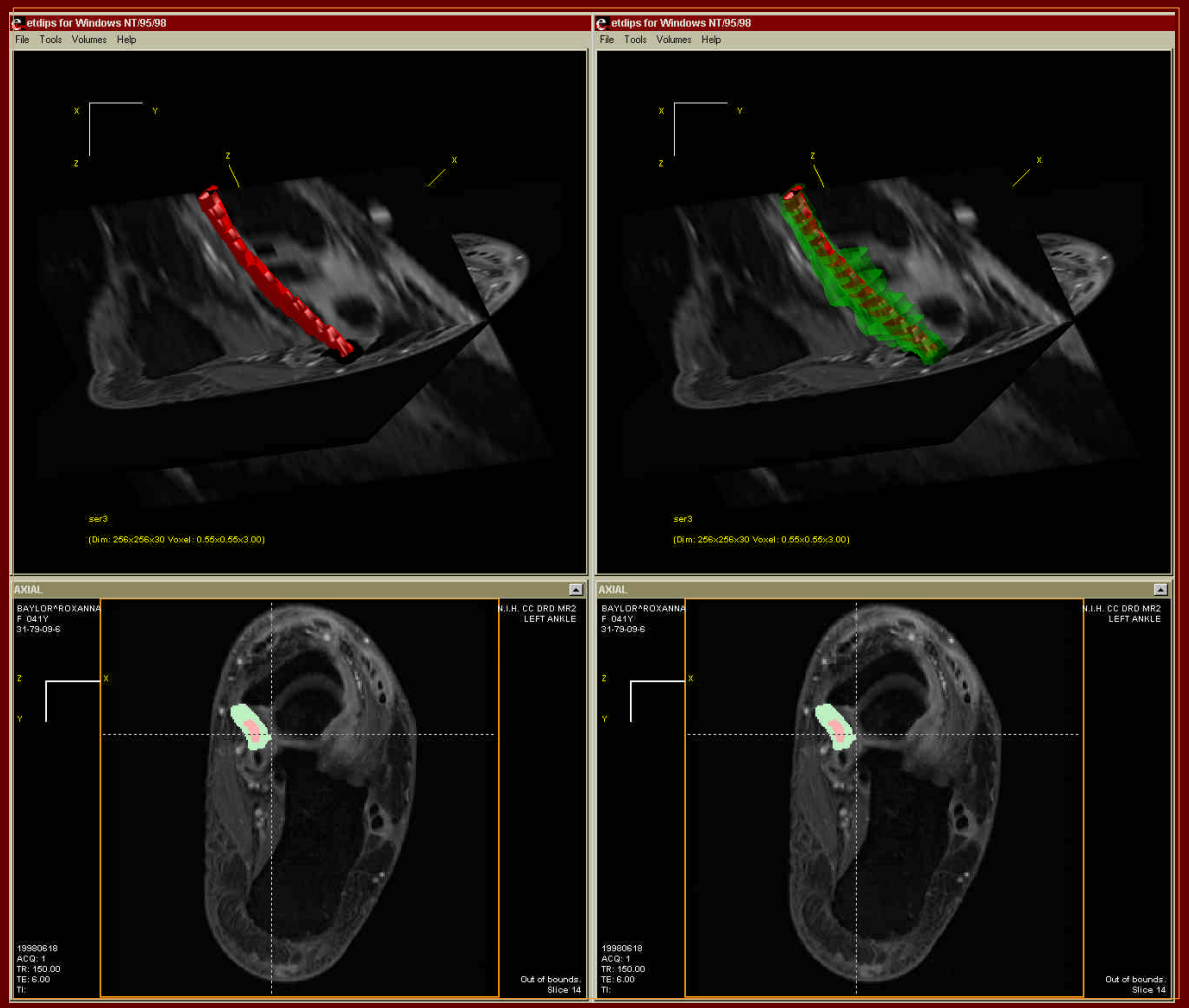

2D vs. 3D

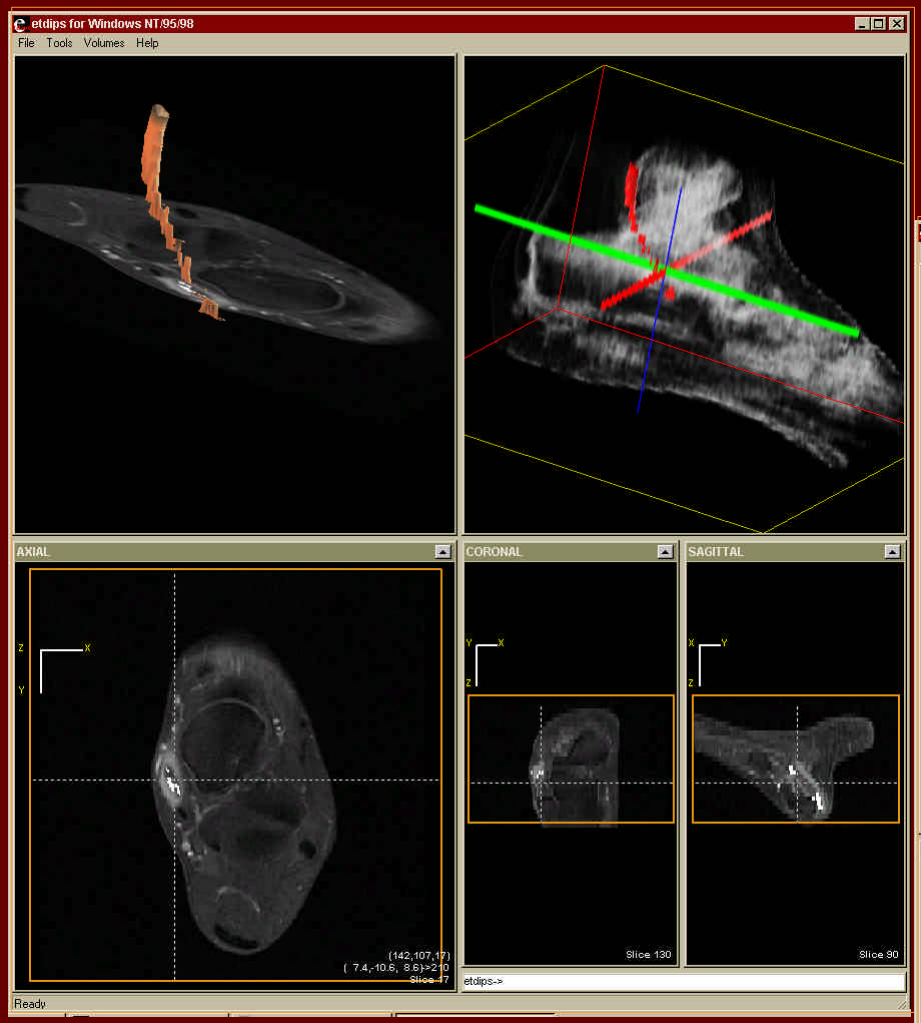

- 3D: Sagittal FMPSPGR (150/6/30/8 - TR/TE/Flip angle/FOV), 2NEX; 256x256x46 0.63x0.63x1.5 mm^3

Elliptical Centric MRA Visualization

Confocal Volume Rendering

- manipulates the opacity composition during ray-casting in two steps to allow the user to visualize only those internal structures which lie within a desired focal band.

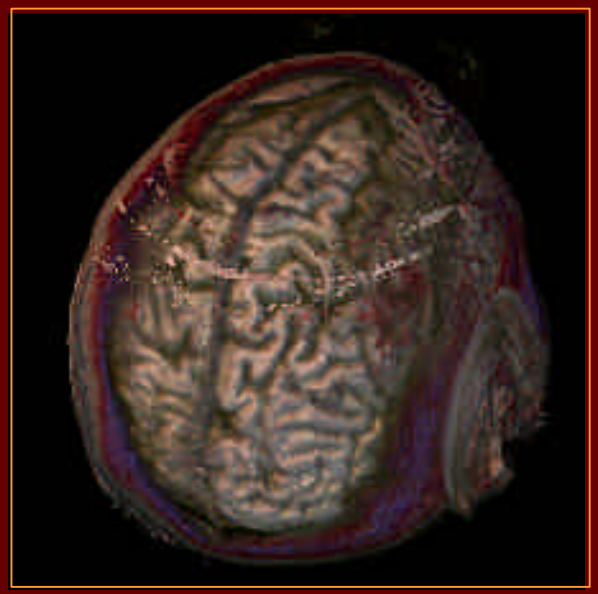

- MR SPGR 256x256x124 0.94x0.94x1.10 mm^3, TR=12.5, TE=5.3
  23 year-old male.

Functional MR Imaging

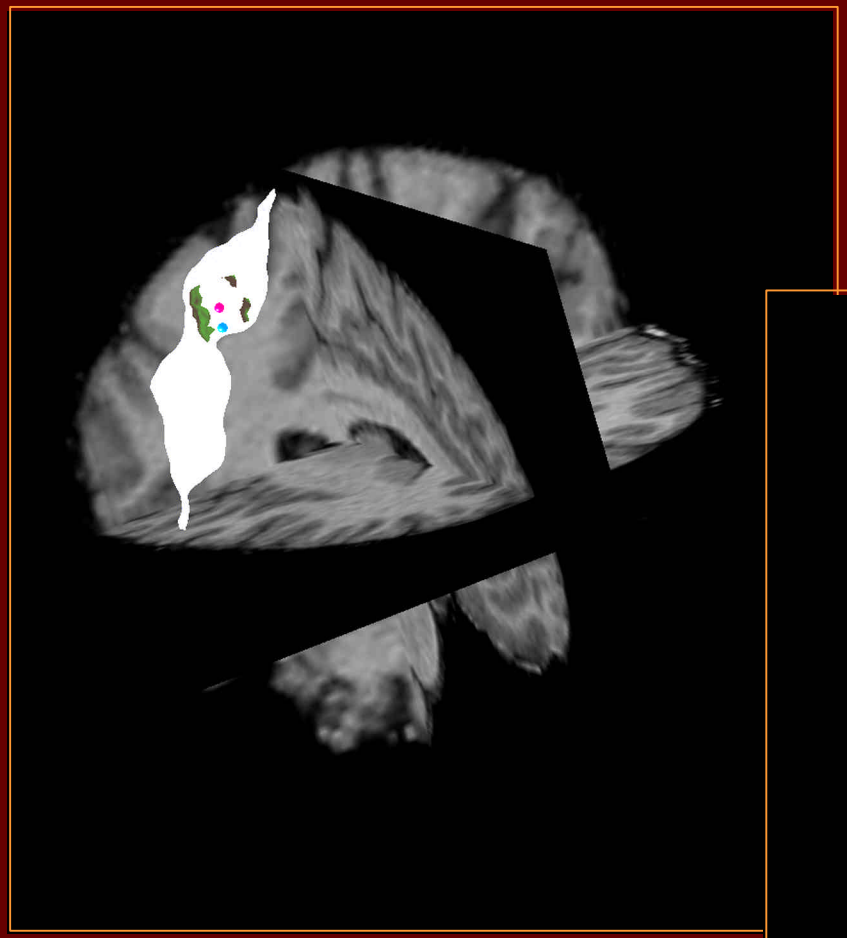

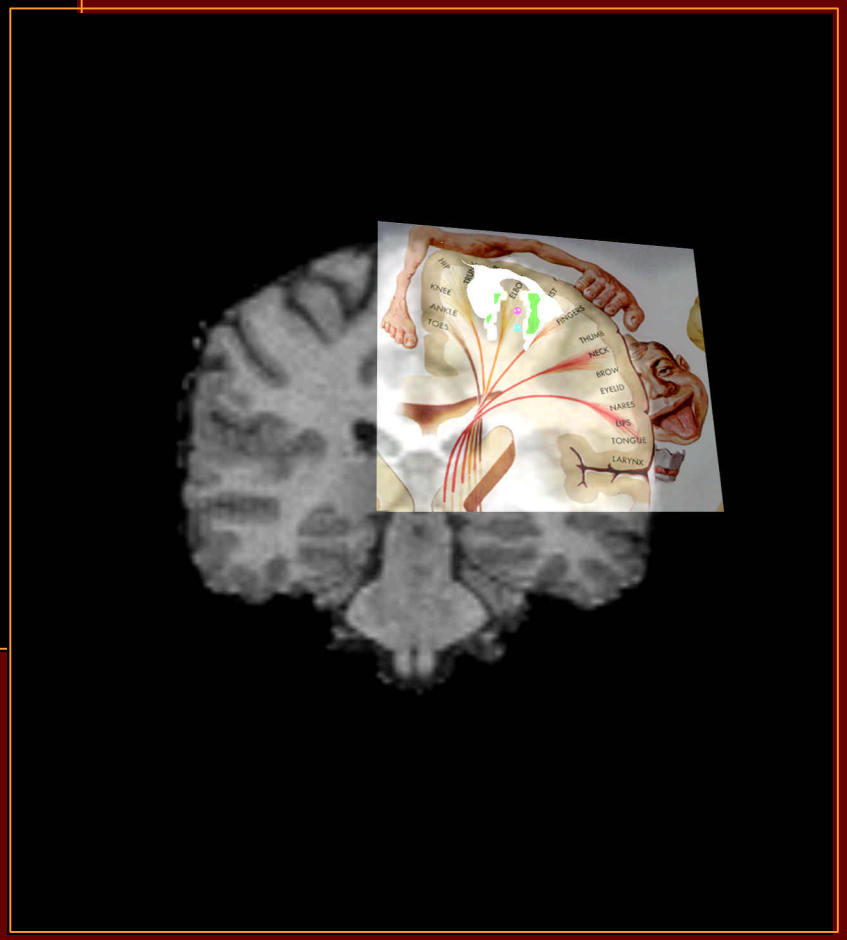
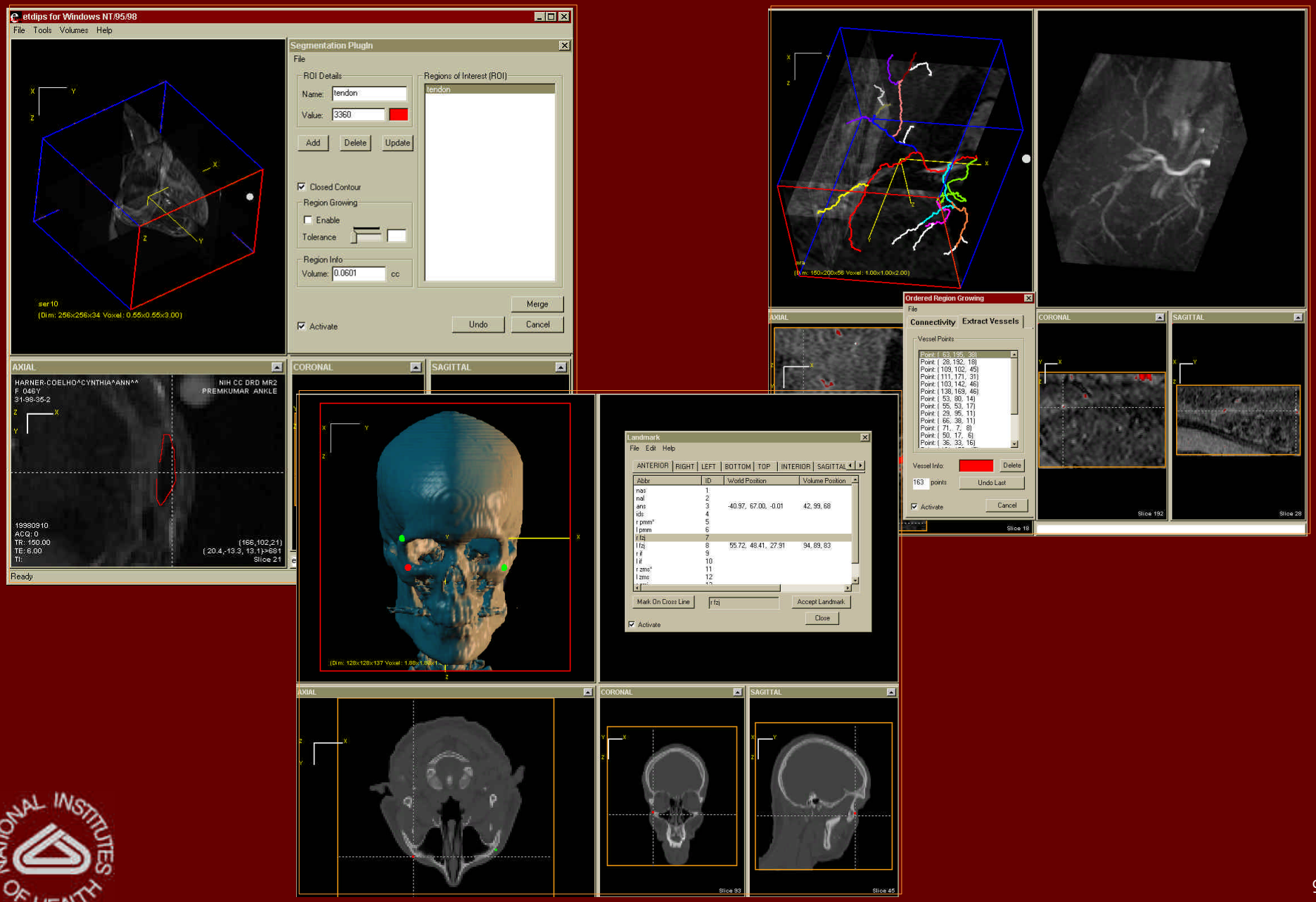
PlugIn Architectures