

## Original Articles

# PERCUTANEOUS RADIO FREQUENCY ABLATION OF SMALL RENAL TUMORS: INITIAL RESULTS

CHRISTIAN P. PAVLOVICH, McCLELLAN M. WALTHER, PETER L. CHOYKE,  
STEPHEN E. PAUTLER, RICHARD CHANG, W. MARSTON LINEHAN AND BRADFORD J. WOOD

*From the Urologic Oncology Branch, National Cancer Institute and Division of Radiology, Warren G. Magnuson Clinical Center, National Institutes of Health, Bethesda, Maryland*

### ABSTRACT

**Purpose:** Thermal tissue ablation with radio frequency energy is an experimental treatment of renal tumor. We report early results of an ongoing trial of percutaneous radio frequency ablation for small renal tumors.

**Materials and Methods:** Patients with percutaneously accessible renal tumors were evaluated for radio frequency ablation. Tumors were solid on computerized tomography (CT), 3 cm. or less in diameter and enlarging during at least 1 year. Ablation was performed at the Interventional Radiology suite under ultrasound and/or CT guidance. A 50 W., 460 kHz. electrosurgical generator delivered radio frequency energy via a percutaneously placed 15 gauge coaxial probe. At least 2, 10 to 12-minute ablation cycles were applied to each lesion. Patients were observed overnight before discharge from hospital and reevaluated 2 months later.

**Results:** A total of 24 ablations were performed in 21 patients with renal tumor, including solid von Hippel-Lindau clear cell tumor in 19 and hereditary papillary renal cancer 2. Most (22 of 24) procedures were performed with patients under conscious sedation. At 2 months postoperatively mean tumor diameter plus or minus standard deviation decreased from  $2.4 \pm 0.4$  to  $2.0 \pm 0.5$  cm. ( $p = 0.001$ ), and a majority of tumors (19 of 24, 79%) ceased to be enhanced on contrast CT. Mean serum creatinine plus or minus standard deviation was unchanged during this interval ( $1.0 \pm 0.2$  mg./dl.). No major and 4 minor complications were encountered, including 2 episodes each of transient psoas pain and flank skin numbness.

**Conclusions:** Percutaneous radio frequency ablation of small renal tumor is well tolerated and minimally invasive. It will remain experimental until procedural and imaging parameters that correlate with tumor destruction are validated.

**KEY WORDS:** kidney neoplasms; carcinoma, renal cell; surgical procedures, minimally invasive

Renal tumors are being detected at increasing rates and smaller sizes with modern imaging techniques. Traditional treatment includes partial or radical nephrectomy but non-surgical ablative modalities are an option for patients with contraindications to surgery. The natural history of renal tumor is variable but those less than 3 cm. rarely metastasize.<sup>1–5</sup> Management options for small renal masses include observation, experimental ablation and surgical removal.

Experimental treatment of small renal tumors includes in situ ablation with high intensity focused ultrasound, cryotherapy or radio frequency energy.<sup>6–8</sup> Although high intensity focused ultrasound for renal tumor has yet to be developed clinically, promising early reports of cryotherapy for renal tumors have been published.<sup>7,9</sup> A vast clinical experience has been obtained with radio frequency ablation of liver neoplasms but renal tumor radio frequency ablation is still in infancy.<sup>10,11</sup> Since Zlotta et al introduced radio frequency ablation for human renal tumor in 1997,<sup>12</sup> early results of percutaneous radio frequency ablation as monotherapy for

renal tumor have been reported, however, experience is limited.<sup>13,14</sup> Intraoperative radio frequency ablation of 11 small (3 cm. or less) renal tumors before surgical removal was recently documented. Pathological signs of necrosis were seen in all but 1 tumor, of which only 35% appeared necrotic.<sup>6</sup> The safety and preliminary efficacy of radio frequency ablation have led to an ongoing trial of percutaneous radio frequency ablation in select patients with small renal tumors.

The need for intervention less morbid than recurrent surgery, dialysis and/or transplantation is particularly acute for patients with hereditary predisposition to renal cell carcinoma, for example von Hippel-Lindau disease or hereditary papillary renal cancer. Multiple recurrent renal tumors may develop in these patients during a lifetime and, thus, form an ideal group in which to study minimally invasive options, such as radio frequency ablation. We continue to provide surgical extirpation as a standard of care for hereditary renal tumors greater than 3 cm. in diameter.<sup>5</sup> Percutaneous radio frequency ablation is offered for smaller solid tumors that demonstrate growth during a 1-year period, and initial results are presented.

### MATERIALS AND METHODS

Patients with a solid renal tumor 3 cm. or less in diameter on computerized tomography (CT) were eligible for the study

Accepted for publication July 27, 2001.

**Editor's Note:** This article is the first of 5 published in this issue for which category 1 CME credits can be earned. Instructions for obtaining credits are given with the questions on pages 312 and 313.

if the tumor demonstrated growth during at least 1 year and had no significant cystic component. All tumors, including those centrally located next to the collecting system, were evaluated for treatment. An interventional radiologist (B. J. W.) determined whether the tumor was percutaneously accessible and safely treatable. Lesions contiguous to bowel or the great vessels were considered unsuitable for treatment. In addition, to be in our study each patient had to have 24-hour creatinine clearance greater than 60 ml. per minute or serum creatinine less than 2.0 mg./dl., undergo standard laboratory evaluation and have a recent CT that was 3 months or less from the date of the procedure. There were 3 patients who had a solitary kidney. Our study met internal review board approval and started accruing cases in the autumn of 1999. Informed consent was obtained from each patient.

Patients received intravenous hydration the night before treatment, as well as antibiotic prophylaxis with oral ciprofloxacin or intravenous ampicillin and gentamicin. Our quaternary referral center recruits patients from all over North America for clinical studies. Therefore, patients were not allowed to travel long distances home until the day after the procedure. A 3 to 5 day outpatient course of oral ciprofloxacin was given if the thermal lesion contacted the collecting system, and outpatient oral pain medications were prescribed as necessary. A followup visit was scheduled at 2 months after the procedure, at which time serum biochemistry, urinalysis, and before and after contrast abdominal CT were obtained. Maximal lesion diameters in the horizontal plane were averaged and used to calculate lesion volume. Contrast CT after the procedure was obtained 80 to 100 seconds after a 120 cc injection of nonionic IV contrast (Oxilan, Cook, Inc., Bloomington, Indiana). Change in enhancement was defined as the difference between post-contrast and post-contrast HU in the lesion.

A single radiologist with extensive percutaneous radio frequency ablation experience (B. J. W.) performed all treatments at the Interventional Radiology suite. Conscious sedation was administered to patients in standard fashion with midazolam, fentanyl and droperidol for all but 2 procedures, which required deep sedation or general anesthesia. Routine hemodynamic monitoring was performed in addition to neurological examination for treatment areas near the psoas muscle. Treatment was performed with ultrasound guidance alone in 9 patients or a combination of CT with or without contrast as needed and real-time ultrasound in 15. The RITA Model 500 electro-surgical generator and RITA Model 70 coaxial probe were used for all treatments except the first 2, in which the Model 30 probe system was used (RITA Medical Systems, Inc., Mountain View, California). The Model 500 generator delivers 50 W., 460 kHz. radio frequency energy, and the Model 30 and 70 probes are insulated 15 gauge coaxial needles consisting of an array of deployable electrodes (fig. 1). Therapy is monitored with feedback from temperature sensitive thermocouples at the treatment margin. Microbubble formation in the treatment area on real-time ultrasound provided a rough estimate of treatment volume, as did immediate CT after treatment, which was performed in 16 patients.

A 22 gauge tandem needle was used as a guide for difficult-to-image lesions, followed by a 15 gauge RITA probe. The multielectrodes were then extruded to 2 to 3 cm. diameters, and radio frequency energy was delivered with a dispersive electrode grounding pad placed on the thigh or buttock. Target probe temperature was set at 100C. Tumors were heated to a maximum wattage of 50 to reach tissue temperatures greater than 70C for a 10 to 12-minute cycle. A second 10 to 12-minute radio frequency cycle was applied to each tumor, with the electrodes repositioned if necessary. For tumors close to 3 cm. in diameter and deep medullary tumors a third 10 to 12-minute cycle was applied if tissue temperatures



FIG. 1. RITA Model 70 probe used for most of percutaneous ablations. Multiple electrodes are deployed in position for radio frequency treatment.

failed to be maintained or achieved. Tumors not reaching at least 70C at the end of therapy were considered poorly treated. Adjacent blood vessels can "insulate" the tumor, preventing proper heating. Replacement of the needle in the tumor or rotation of the needle tines can sometimes improve tumor heating. Finally, as the treatment probe is withdrawn, radio frequency energy is again applied to cauterize the intraparenchymal needle track to limit back bleeding and external needle track to limit tumor seeding.

Patients undergo imaging at 3, 6 and 12 months after treatment to follow the evolution of the managed tumor. Serum creatinine, creatinine clearance and differential renal scan are obtained at 6 and 12-month followup. Patients with enhancing enlarging tumors after therapy may undergo re-treatment with radio frequency ablation or surgical resection. All data are presented as mean values plus or minus standard deviation (SD). The Wilcoxon matched pairs signed rank test was used to analyze differences in various parameters before and after treatment with commercial software.

## RESULTS

*Treatment.* A total of 26 patients met the criteria for entry into the trial. There were 5 patients who had tumors in positions that were determined to be unsafe for percutaneous radio frequency ablation. Of the treated patients there were 13 men and 8 women with a mean age of 39 years. Due to referral patterns at our institution, all patients in this series had hereditary forms of renal cell carcinoma, including von Hippel-Lindau disease in 19 and hereditary papillary renal cancer in 2. A total of 24 renal tumors were managed percutaneously (table 1). Each tumor was treated only once, with 1 ablated in 18 patients and 2 in 3. Of the patients with greater than 1 tumor treated 2 underwent simultaneous treatment of tumors in the same kidney and 1 had a tumor in each kidney treated 6 months apart. Radio frequency ablation was never

TABLE 1. Patient data

Pt. No.—Age	Diagnosis	Renal Tumor				
		Side	Pole	Location	Exophytic	Depth
1—49	von Hippel-Lindau disease	Rt.	Upper, lower	Postero-lateral	Yes	Cortico-medullary
2—35	von Hippel-Lindau disease	Rt.	Inferior	Postero-lateral	Yes	Cortical
		Lt.	Mid	Anterior	No	Cortico-medullary
3—67	von Hippel-Lindau disease	Rt.	Upper	Postero-lateral	No	Cortico-medullary
4—37	von Hippel-Lindau disease	Rt.	Upper	Postero-lateral	Yes	Cortical
5—27	Hereditary papillary renal Ca	Rt.	Upper	Postero-lateral	No	Cortico-medullary
6—61	von Hippel-Lindau disease	Lt.	Mid	Anterior	Yes	Cortico-medullary
7—28	von Hippel-Lindau disease	Lt.	Lower	Postero-lateral	No	Medullary
8—44	von Hippel-Lindau disease	Rt.	Mid	Postero-lateral	Yes	Cortical
9—28	von Hippel-Lindau disease	Rt.	Lower	Postero-lateral	Yes	Cortical
10—34	von Hippel-Lindau disease	Rt.	Mid	Anterior	No	Medullary
11—47	von Hippel-Lindau disease	Rt.	Upper	Postero-lateral	Yes	Cortical
12—35	Hereditary papillary renal Ca	Lt.	Lower	Anterior	No	Cortico-medullary
13—43	von Hippel-Lindau disease	Lt.	Lower	Anterior	No	Medullary
14—47	von Hippel-Lindau disease	Lt.	Lower	Postero-lateral	Yes	Cortico-medullary
15—35	von Hippel-Lindau disease	Rt.	Lower	Postero-lateral	Yes	Cortico-medullary
16—24	von Hippel-Lindau disease	Lt.	Lower	Postero-lateral	No	Cortico-medullary
17—19	von Hippel-Lindau disease	Lt.	Upper	Postero-lateral	Yes	Cortical
18—36	von Hippel-Lindau disease	Rt.	Upper	Postero-lateral	Yes	Cortical
19—58	von Hippel-Lindau disease	Rt.	Mid	Postero-lateral	No	Medullary
20—23	von Hippel-Lindau disease	Lt.	Upper	Postero-lateral	Yes	Cortical
21—46	von Hippel-Lindau disease	Lt.	Lower	Postero-lateral	Yes	Cortical

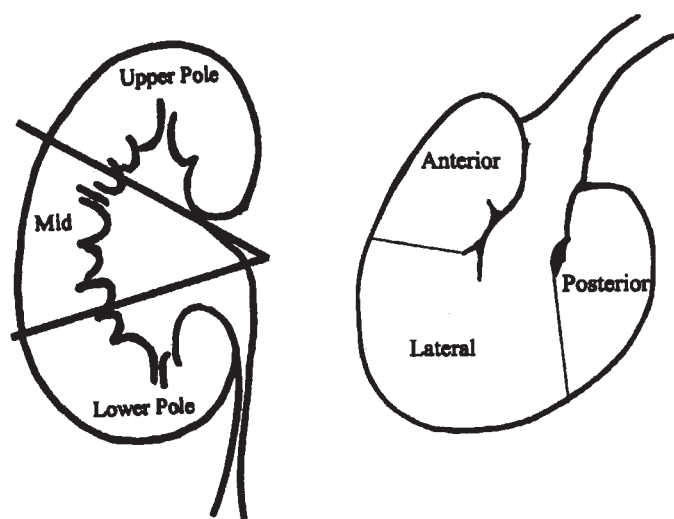


FIG. 2. Kidney for assessment of tumor location

performed on kidneys at the same time. Tumors were classified as upper pole, mid or lower pole, anterior or postero-lateral (fig. 2), exophytic or not, and in terms of increasing depth, including cortical, cortico-medullary and medullary (table 1). All tumors were spherical or slightly ovoid on CT. The starting mean diameter of the tumor plus or minus SD was  $2.4 \pm 0.4$  cm. (median 2.5), which equated to a mean volume plus or minus SD of  $7.4 \pm 3.5$  cm.<sup>3</sup> (median 7.2, table 2).

Of the 24 ablations 19 were considered satisfactory by a quality of treatment assessment at the treatment site by the interventional radiologist. A satisfactory treatment was one in which the lesion was accurately targeted and tissue temperatures 70C or greater were maintained at all probe electrodes during therapy. In 5 cases optimal tissue temperature was either not reached or maintained at each electrode and considered poor treatment. During the procedure, managed areas became progressively hyperechogenic on ultrasound, which provided a rough visual method of monitoring treatment progress and probe location (fig. 3).

**Treatment efficacy.** Preliminary efficacy was assessed with abdominal CT 2 months after treatment (figs. 4 and 5). There were 2 radiographic parameters evaluated during this interval, including a change in lesion enhancement (difference in

HU) and lesion size (table 2). No localized tumor dissemination was observed on CT or with physical examination. Median tumor difference in HU before treatment was 62.0 (mean plus or minus SD  $64.1 \pm 25.6$ ), as was expected for solid vascular tumors. After treatment the median difference in HU of the lesions decreased to 6.5 (mean plus or minus SD  $15.7 \pm 24.0$ ). The majority of treated tumors did not enhance after radio frequency ablation, with a difference in HU of less than 12 for 19 of 24 (79%) tumors. There were 5 tumors that maintained focal areas of persistent enhancement.

Mean lesion diameter plus or minus SD decreased from  $2.4 \pm 0.4$  to  $2.0 \pm 0.5$  cm. (range 1.5 to 3.0 and 1.2 to 2.8, respectively) 2 months after percutaneous radio frequency ablation ( $p = 0.001$ ). Calculated average lesion volumes decreased accordingly from  $7.4 \pm 3.5$  to  $4.7 \pm 2.9$  cm.<sup>3</sup> (range 1.6 to 14.1 and 0.9 to 10.9, respectively,  $p = 0.002$ ) after treatment (median 4.2). Of the 5 tumors with focal areas of persistent enhancement on 2-month CT 4 were thought to have been unsatisfactorily ablated by the treating radiologist. A fifth tumor considered satisfactorily managed was focally enhanced 2 months after treatment (table 2). Conversely, 1 tumor that did not enhance after radio frequency ablation was thought to have been inadequately ablated after the procedure, which was due to tumor heating to only 60 to 65C. Other than these 2 examples, immediate assessment of management at the treatment site was predictive of 2-month ablation success with imaging criteria. Clinically and radiographically, neither metastatic disease nor any signs of tumor in the treatment tracks were noted on followup.

**Effects on the kidney.** Urine dipstick and microscopic analyses were performed before and 2 months after radio frequency ablation in 17 patients. No patients had microscopic hematuria greater than 5 red blood cells per high power field but 4 had microscopic proteinuria (1+) on dipstick analysis that was not present before radio frequency ablation. There was 1 patient who had an episode of gross hematuria 2 hours after the procedure. The patient had a normal urinalysis 2 months later without interval complaints. The mean serum creatinine of the group did not change 2 months after radio frequency ablation ( $1.0 \pm 0.2$  mg./dl. [range 0.6 to 1.4 and 0.7 to 1.3],  $p = 0.9$ , normal range 0.9 to 1.4), and no patient had an increase in serum creatinine greater than 0.1 mg./dl.

**Complications.** All patients were medically ready for discharge from the hospital within 24 hours of radio frequency ablation. Each patient was discharged home the day after treatment, except for 1 who stayed a day longer for social reasons. The typical patient had nausea and mild pain for 4

TABLE 2. Treatment parameters

Pt. No.	Treatment No.	Imaging	Quality	Before Ablation			2 Mos. After Ablation		
				HU Difference	Diameter (cm.)	Vol (cm. <sup>3</sup> )	HU Difference	Diameter (cm.)	Vol. (cm. <sup>3</sup> )
1	1	CT, sonogram	Satisfactory	70	2.5	7.7	6	2.1	4.5
1	2	CT, sonogram	Poor	73	2.5	8.2	85	2.3	6.0
2	3	CT, sonogram	Satisfactory	56	3.0	13.4	29	2.3	6.0
2	15	CT, sonogram	Poor	84	2.6	8.7	0	2.5	8.2
3	4	CT, sonogram	Satisfactory	55	2.1	4.5	4	1.2	0.9
4	5	CT, sonogram	Satisfactory	62	2.5	8.2	10	1.3	1.0
5	6	CT, sonogram	Satisfactory	44	2.8	10.9	2	2.8	10.9
6	7	CT, sonogram	Satisfactory	24	2.9	12.8	0	2.5	7.7
7	8	CT, sonogram	Satisfactory	69	2.2	5.2	4	1.6	1.9
8	9	CT, sonogram	Satisfactory	48	2.3	6.0	0	2.6	9.2
8	10	CT, sonogram	Satisfactory	33	2.5	8.2	7	1.9	3.3
9	11	Sonogram	Satisfactory	44	2.3	6.4	5	1.8	2.8
10	12	Sonogram	Poor	114	2.8	11.5	68	1.5	1.6
11	13	Sonogram	Satisfactory	29	2.7	10.3	3	2.4	6.8
12	14	Sonogram	Satisfactory	Not applicable	2.3	6.4	1	2.0	4.2
13	16	CT, sonogram	Poor		86	2.8	69	2.1	4.5
14	17	Sonogram	Satisfactory	67	2.4	6.8	11	2.6	8.7
15	18	Sonogram	Satisfactory	80	2.5	8.2	0	2.5	7.7
16	19	CT, sonogram	Satisfactory	38	1.5	1.6	9	1.6	1.9
17	20	Sonogram	Satisfactory	49	2.3	6.4	9	1.6	2.1
18	21	CT, sonogram	Satisfactory	126	1.6	2.1	10	1.4	1.3
19	22	Sonogram	Poor	86	3.0	14.1	31	*	*
20	23	CT, sonogram	Satisfactory	54	1.8	2.8	4	1.9	3.6
21	24	Sonogram	Satisfactory	83	1.8	2.8	9	2.0	3.9

\* Not accurately quantifiable due to irregular after treatment margins.

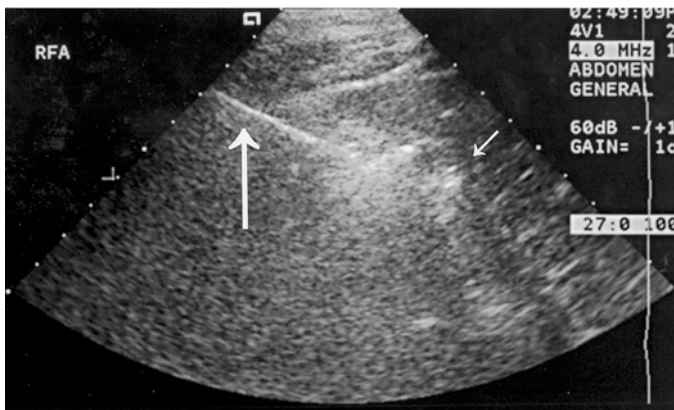


FIG. 3. Ultrasound guided radio frequency ablation. Probe (bold arrow) has been inserted into center of tumor. Microbubbles are beginning to form around probe electrodes (thin arrows).

to 8 hours after the procedure but pain at the treatment site was widely variable and not predictable by size or location. Prior ipsilateral flank surgery was associated with a higher degree of pain after the procedure. Nausea was the most common complaint during this time, and experienced by a majority of the patients and possibly related to sedatives that were used for the procedure. Nevertheless, most patients were able to tolerate dinner the night of the procedure and all tolerated a regular diet by morning. Flank pain postoperatively was described as a mild to moderate burning, which also resolved by morning.

Minor complications postoperatively occurred in 4 patients, including pain on flexion of the hip on the treated side in 2 and areas of ipsilateral cutaneous flank numbness 2. Pain on thigh flexion resolved by 48 hours and 2 weeks, respectively, whereas the areas of cutaneous numbness persisted at 2-month followup. Treatment proximity to psoas and ilioinguinal or iliohypogastric nerves may have predisposed to these minor complications in patients with tumors abutting these areas. Another patient passed a dark stool 1-week postoperatively from an upper gastrointestinal source.

There were no clinical or radiographically detected major complications. Specifically, no damage to adjacent organs or

major structures was noted on imaging during, immediately after or 2 months after the procedure except in a few cases. A small (1.5 cm.) perinephric hematoma was noted immediately after 1 case, which resolved uneventfully by 2-month CT. We attempted to manage several mm. margin surrounding each tumor. However, in 4 cases followup CT demonstrated slightly more extensive collateral damage to the ipsilateral kidney parenchyma. These areas were small compared to remaining ipsilateral normal kidney parenchyma, which was less than 10%, and were usually wedge shaped, consistent with radio frequency ablation induced ischemic damage to the local intra-arterial system. There were 2 patients who had thin rims, which were less than 0.5 cm., of neighboring liver ablated. One exophytic suprarenal tumor was managed without radiographic damage to the neighboring adrenal gland. No damage to the main renal arterial or venous system was noted.

#### DISCUSSION

Preliminary experience with percutaneous radio frequency ablation for small renal tumors is presented. There were 24 tumors managed in 21 patients with hereditary renal cell carcinoma. Percutaneous radio frequency ablation was offered to obviate or delay surgery, or as an alternative to observation. The feasibility, preliminary efficacy and minimal morbidity of percutaneous radio frequency ablation are demonstrated. Treatment was well tolerated, and patients had a short recovery time that was less than 24 hours. At 2-month followup 19 of 24 treated lesions showed no significant contrast enhancement and had become smaller in size. No clinically significant renal or collateral damage was detected by serum, urine or CT analysis. No urinary fistulas were observed.

Tumor destroyed with radio frequency ablation or cryotherapy may take months to regress, while the surgical bed after open partial nephrectomy may leave a defect that enhances on CT.<sup>7,15</sup> It is encouraging that all but 1 (18 of 19) of the tumors thought to have been satisfactorily managed at the time of the procedure, with tissue temperatures 70C or greater, lost contrast enhancement 2 months after treatment, with a difference in HU of less than 12. The clinical significance of focal contrast uptake in the remaining tumors is not known. However, hepatic radio frequency ablation

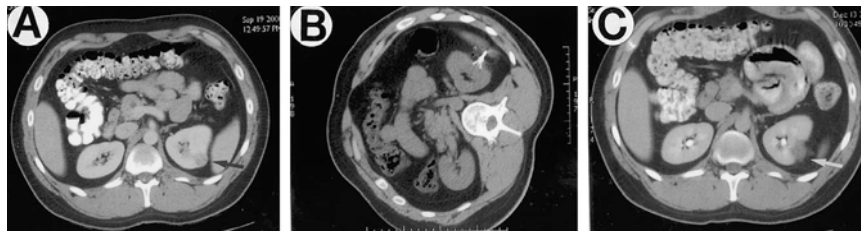


FIG. 4. CT before, during and after radio frequency ablation (patient 20, treatment 23). *A*, after contrast CT 1 month before treatment indicates solid enhancing tumor (difference in HU 54) in lateral aspect of left kidney (black arrow). *B*, patient in right lateral decubitus position during treatment and probe electrodes are deployed in tumor. *C*, 2-month followup after contrast CT lesioned area remains visible (white arrow) but no longer enhances (difference in HU 4).

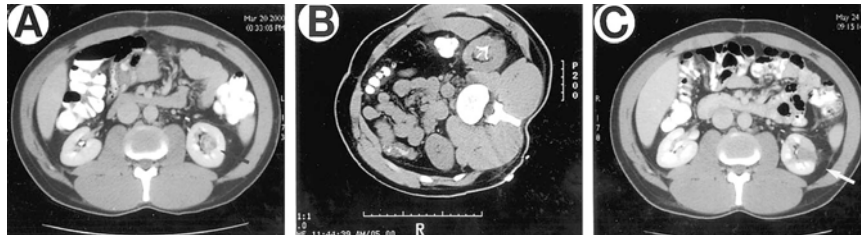


FIG. 5. CT. *A*, day before radio frequency ablation (patient 7, treatment 8), with 2.2 cm. medullary tumor (black arrow) representing significant pretreatment enhancement (difference in HU 69). *B*, during radio frequency ablation. *C*, 2 months after radio frequency ablation. After treatment lesion has decreased in diameter to 1.6 cm. (white arrow) and lost contrast enhancement (difference in HU 4). Cauterized needle track is still visible 2 months after ablating central tumor (white arrow).

studies suggest that the lack of contrast enhancement on CT pathologically correlates with complete tumor necrosis. Long-term clinical and radiographic followup will be required to determine the natural history of renal tumors managed with radio frequency ablation.

Radio frequency ablation induces ionic agitation, frictional heat and cell death by coagulative necrosis.<sup>6, 12, 16, 17</sup> Pathological analysis done in 24 hours of renal tumor radio frequency ablation demonstrates pyknosis, stromal edema, and loss of nucleoli and nuclear detail in the treatment zone.<sup>6, 18</sup> Later, changes consistent with coagulative necrosis become more apparent.<sup>12, 17, 18</sup> In the clinical treatment of liver tumors the lack of enhancement on CT correlated with pathological coagulative necrosis to within 2 mm., while ultrasound was not an accurate predictor of the treatment zone.<sup>18</sup> Interstitial saline has been used for electrode augmentation in the kidney.<sup>19</sup> However, in our experience this method is not necessary for small tumors, and may result in less predictable and uniform thermal lesions. Future analysis of treatment parameters, including probe type, tissue temperature and impedance, tumor location, and imaging, will better define the requirements for successful radio frequency ablation of human renal tumor.

A recent series of 9 tumors in 8 patients demonstrated the short-term efficacy of large renal tumor radio frequency ablation with a water cooled radio frequency system.<sup>14</sup> That system has 200 W. and a single 17.5 gauge needle probe internally perfused with chilled saline to limit charring and increase energy deposition. In this study ablation was more complete for exophytic tumors and the 3 tumors 3 cm. or less in diameter, while larger tumors required staged management. There is no doubt that the smaller and more uniform tumors in our series facilitated 1 session radio frequency ablation. Exophytic tumors were more successfully treated in our series as well but 10 of 14 central, including medullary or cortico-medullary, tumors were also satisfactorily ablated with 1 session. Management of anterior tumor was limited by concern regarding heat effects on contiguous bowel, ureter or hilar vessels. Nevertheless, 5 anterior tumors were treated in our series, including 3 that show no enhancement at 2-month followup. For anterior and/or exophytic tumors a generous amount of perinephric fat may insulate the treated area and

shield adjacent structures from collateral damage. For patients in whom percutaneous access is difficult or hazardous, for example thin patients with anterior tumors, laparoscopy assisted radio frequency ablation may become a reasonable option.

Currently, several companies market more powerful energy delivery systems and various probes capable of up to 5 cm. thermal ablation. Our study has now broadened to include these higher wattage radio frequency ablation systems as well as probes of various configurations. In the future treatment failures, and complications might be reduced with radio frequency delivery systems more precisely tailored to specific tumors and locations. Higher wattage systems may allow ablative target temperatures to be reached in virtually all tumors, regardless of location or vascularity.

Current standards dictate that patients with hereditary renal neoplasms be observed until the largest tumor reaches 3 cm., at which time all lesions in that kidney are enucleated. With this strategy we have seen no metastatic renal cancer in greater than 52 patients with hereditary renal cancer to date.<sup>5, 20</sup> Percutaneous radio frequency ablation may provide a new alternative for renal masses approaching this 3 cm. threshold and also be an option for sporadic renal tumor in poor surgical candidates.

Our group has performed greater than 1,000 tumor enucleations in patients with von Hippel-Lindau disease and hereditary papillary renal cancer, and found tumor histology in these cohorts to be entirely reproducible. Solid renal tumors on CT in patients with von Hippel-Lindau disease are invariably clear cell neoplasms, and in families with hereditary papillary renal cancer represent basophilic papillary renal cell carcinoma.<sup>21, 22</sup> Thus, tumor histology in our present series was predictable without resorting to biopsy before treatment. Biopsy after treatment was not performed due to sampling error and morbidity concerns. Instead, the study algorithm included the interval before and after contrast imaging, followed by repeat radio frequency ablation for any lesion that persistently enhanced or surgery for any that grew greater than 3 cm. Although this series is small and preliminary, we remain cautiously optimistic about these early results. Higher patient accrual and further followup will determine whether radio frequency ablation pro-

vides efficacious treatment of small renal tumors in specific clinical settings.

#### CONCLUSIONS

Radio frequency ablation of small renal tumors is minimally morbid and well tolerated in patients with percutaneously accessible lesions. The vast majority of managed tumors did not enhance and had decreased or stabilized in size on 2-month followup CT. The natural history of managed lesions and predictors of successful radio frequency ablation treatment outcome remain to be determined. If long-term results are favorable radio frequency ablation should prove to be an attractive treatment option for small renal masses in patients at risk for multiple renal tumors or with other relative contraindications to surgery.

Kathy Hurley and Igor Mikityansky provided technical assistance. Drew Pautler designed the illustrations for figure 2.

#### REFERENCES

1. Bosniak, M. A.: Observation of small incidentally detected renal masses. *Semin Urol Oncol*, **13**: 267, 1995
2. Choyke, P. L., Glenn, G. M., Walther, M. M. et al: The natural history of renal lesions in von Hippel-Lindau disease: a serial CT study in 28 patients. *AJR Am J Roentgenol*, **159**: 1229, 1992
3. Rendon, R. A., Stanietzky, N., Panzarella, T. et al: The natural history of small renal masses. *J Urol*, **164**: 1143, 2000
4. Frank, W., Guinan, P., Stuhldreher, D. et al: Renal cell carcinoma: the size variable. *J Surg Oncol*, **54**: 163, 1993
5. Walther, M. M., Choyke, P. L., Glenn, G. et al: Renal cancer in families with hereditary renal cancer: prospective analysis of a tumor size threshold for renal parenchymal sparing surgery. *J Urol*, **161**: 1475, 1999
6. Walther, M. C., Shawker, T. H., Libutti, S. K. et al: A phase 2 study of radio frequency interstitial tissue ablation of localized renal tumors. *J Urol*, **163**: 1424, 2000
7. Gill, I. S., Novick, A. C., Meraney, A. M. et al: Laparoscopic renal cryoablation in 32 patients. *Urology*, **56**: 748, 2000
8. Susani, M., Madersbacher, S., Kratzik, C. et al: Morphology of tissue destruction induced by focused ultrasound. *Eur Urol*, suppl., **23**: 34, 1993
9. Shingleton, W. B. and Sewell, P. E., Jr.: Percutaneous renal tumor cryoablation with magnetic resonance imaging guidance. *J Urol*, **165**: 773, 2001
10. Curley, S. A., Izzo, F., Ellis, L. M. et al: Radiofrequency ablation of hepatocellular cancer in 110 patients with cirrhosis. *Ann Surg*, **232**: 381, 2000
11. Bilchik, A. J., Rose, D. M., Allegra, D. P. et al: Radiofrequency ablation: a minimally invasive technique with multiple applications. *Cancer J Sci Am*, **5**: 356, 1999
12. Zlotta, A. R., Wildschutz, T., Raviv, G. et al: Radiofrequency interstitial tumor ablation (RITA) is a possible new modality for treatment of renal cancer: ex vivo and in vivo experience. *J Endourol*, **11**: 251, 1997
13. McGovern, F. J., Wood, B. J., Goldberg, S. N. et al: Radio frequency ablation of renal cell carcinoma via image guided needle electrodes. *J Urol*, **161**: 599, 1999
14. Gervais, D. A., McGovern, F. J., Wood, B. J. et al: Radiofrequency ablation of renal cell carcinoma: early clinical experience. *Radiology*, **217**: 665, 2000
15. Kshirsagar, A. V., Choyke, P. L., Linehan, W. M. et al: Pseudotumors after renal parenchymal sparing surgery. *J Urol*, **159**: 1148, 1998
16. Patterson, E. J., Scudamore, C. H., Owen, D. A. et al: Radiofrequency ablation of porcine liver in vivo: effects of blood flow and treatment time on lesion size. *Ann Surg*, **227**: 559, 1998
17. Scudamore, C. H., Lee, S. I., Patterson, E. J. et al: Radiofrequency ablation followed by resection of malignant liver tumors. *Am J Surg*, **177**: 411, 1999
18. Goldberg, S. N., Gazelle, G. S., Compton, C. C. et al: Treatment of intrahepatic malignancy with radiofrequency ablation: radiologic-pathologic correlation. *Cancer*, **88**: 2452, 2000
19. Polascik, T. J., Hamper, U., Lee, B. R. et al: Ablation of renal tumors in a rabbit model with interstitial saline-augmented

radiofrequency energy: preliminary report of a new technology. *Urology*, **53**: 465, 1999

20. Herring, J. C., Enquist, E. G., Chernoff, A. et al: Parenchymal sparing surgery in patients with hereditary renal cell carcinoma: 10-year experience. *J Urol*, **165**: 777, 2001
21. Poston, C. D., Jaffe, G. S., Lubensky, I. A. et al: Characterization of the renal pathology of a familial form of renal cell carcinoma associated with von Hippel-Lindau disease: clinical and molecular genetic implications. *J Urol*, **153**: 22, 1995
22. Lubensky, I. A., Schmidt, L., Zhuang, Z. et al: Hereditary and sporadic papillary renal carcinomas with c-met mutations share a distinct morphological phenotype. *Am J Pathol*, **155**: 517, 1999

#### EDITORIAL COMMENT

New minimally invasive technologies are being applied to nephron sparing surgery for renal tumors to decrease operating time, pain, morbidity and hospital stay. Tumor ablative treatment modalities include cryosurgery, radio frequency ablation, high intensity focused ultrasound, and laser and microwave coagulation. These modalities are being administered laparoscopically or percutaneously and, ultimately, complete extracorporeal methods may be developed. Each of these modalities is limited by the ability to image the destructive process precisely as it is being administered, thereby minimizing injury to normal adjacent parenchyma, while ensuring complete destruction of the offending lesion.

The ablative modality with which the most experience has been gained for treatment of renal tumors is cryosurgery. Initial experimental studies at our center evaluated the efficacy of intraparenchymal cryoablative therapy with or without renal artery occlusion in mongrel dogs.<sup>1</sup> Effective renal tissue ablation was confirmed at the treatment site in all instances. Renal artery occlusion did not significantly alter the freezing process and provided no practical advantage. Our group subsequently embarked on a clinical trial of laparoscopic renal cryoablation in carefully select patients with a single small (less than 4 cm.), solid, peripheral localized renal tumor. This trial was initiated in 1997, and follow-up after treatment is greater than 3 years in many patients (reference 7 in article). Our patients have been followed closely with sequential magnetic resonance imaging and percutaneous biopsy of the cryoablated renal tumor at 6 months postoperatively. In our initial series of 50 patients sequential magnetic resonance imaging demonstrated gradual contraction in the size of the cryolesion in all but 1 patient, and percutaneous biopsy of the cryoablated renal tumor site demonstrated residual malignancy in this patient. All other postoperative percutaneous biopsies have been negative for malignancy. There have been no other instances of tumor recurrence, and all patients are being subjected to close clinical and radiographic followup.

Pavlovich et al describe preliminary outcome data with percutaneous Radio Frequency Ablation for small renal tumors. The study population comprised patients with von Hippel-Lindau disease with solid tumors less than 3 cm. This study group is appropriate since the risk of metastasis in this setting is low. The clinical trial was not preceded by evaluation of this technique in an experimental animal model. A total of 21 patients were treated with Radio Frequency Ablation, however, followup is only 2 months. The finding of persistent CT enhancement on 5 renal tumors after Radio Frequency Ablation is of concern in regard to residual malignancy. We have not observed this finding in renal tumors ablated with cryotherapy. Percutaneous biopsy of the treatment site in these patients might enable earlier diagnosis and treatment of residual malignancy. Although percutaneous Radio Frequency Ablation appears to be safe, it remains experimental until validation of tumor destruction is demonstrated by longer term outcome data. Ultimately, any new nephron sparing treatment modality must demonstrate clinical and pathological success rates comparable to those reported after open partial nephrectomy before it can be considered as established therapy for renal tumors.

*Andrew C. Novick  
Department of Urology  
Cleveland Clinic Foundation  
Cleveland, Ohio*

1. Campbell, S. C., Krishnamurthi, V., Chow, G. et al: Renal cryosurgery: experimental evaluation of treatment parameters. *Urology*, **52**: 29, 1998